

## Systematic Review

# PERCUTANEOUS, THERMAL, AND PULSED RADIOFREQUENCY FOR NONMALIGNANT HIP PAIN

Gary Kao, MD<sup>1</sup>, Jerry Kalangara, MD<sup>2</sup>, and Anna Woodbury, MD<sup>2</sup>

**Background:** Although radiofrequency (RF) has been used to treat several types of chronic osteoarthritic pain, the role of percutaneous thermal RF ablation and pulsed RF in treating nonmalignant hip pain has not been well established.

**Objective:** To estimate the effectiveness of thermal and pulsed RF therapy in treating nonmalignant hip pain and encourage further research.

**Study Design:** A systematic review of English and non-English articles was performed on 1/20/2017 using the following databases: PubMed (1960-2017), Cochrane Controlled Trials Register (1960-2017), and EMBASE (1966-2017). Studies for which complete articles were not accessible were excluded if primary authors could not be successfully contacted after attempts via at least 2 different mediums. Search terms included RF, hip, and human ("radiofrequency"[All Fields] AND ("hip"[MeSH Terms] AND "humans"[MeSH Terms])).

**Results:** Two clinical trials for hip RF (n = 32) and a collection of 7 case series or studies (n

= 25) met our inclusion criteria. Both trials used percutaneous RF of the periarticular sensory branches of the obturator and femoral nerves near the hip joint. Ten studies were found to be eligible after screening title, abstract, and full text for inclusion and exclusion criteria. Both clinical trials saw improved post procedure pain scores when compared with standard conservative treatment for inoperable chronic hip pain. The overall complication rate of pooled cohort of all cases reviewed was 9.5% (6/57), but did not result in any self-reported injury.

**Conclusions:** There is low quality evidence to suggest that thermal or pulsed RF therapy is a suitable option for chronic inoperable hip pain. Higher quality trials are needed for stronger recommendations.

**Key words:** Radiofrequency, ablation, hip, pain, coxalgia, review, chronic, inoperable, nonsurgical, femoral, obturator

Joint pain is particularly debilitating due to constant pain triggered from movement and functional limitations experienced by patients due to pain. Possible solutions include surgery, conservative management (via conventional medication), and neurolysis. The etiology of hip joint pain can be varied to include: oncological (primary or secondary) causes, auto-inflammatory arthropathies, post operative coxarthralgia, avascular necrosis, or osteoarthritis (OA). For most patients, a definitive solution lies in total hip

arthroplasty. However, there are situations in which surgery is contraindicated due to medical comorbidities including but not limited to: obesity, age extremes, smoking, chronic anticoagulation, and patient preference. For these patients, conventional medication may be ineffective or carry too many adverse effects at effective doses to be a feasible solution. Neurolysis may be a viable option for pain relief in this subset of patients and can be accomplished via surgical, chemical, RF thermocoagulation, or cryoablation techniques (1,2).

OA of the hip is associated with a high individual (increased mortality) and societal (health care economic) burden (3,4). OA of the hip and knee represents the primary etiology of walking-related disability in the United States (5). Quality of life is especially affected among patients with hip OA, due to limited ambulation and daily activity. While the prevalence of hip OA varies according to age, gender, and other

From : <sup>1</sup>Pain Management Fellow, Mount Sinai West, New York, NY; <sup>2</sup>Division of Pain Management, Department of Anesthesiology, Emory University, Veterans Affairs Medical Center, Atlanta, GA

Author for correspondence: Anna Woodbury, MD  
Address: Department of Anesthesiology, Veterans Health Administration, 1670 Clairmont Rd NE, Decatur, GA 30033  
E-mail: anna.woodbury@emory.edu

factors, it is recognized to be high. One prior study estimates age-dependent prevalence of 28 to 43% radiologically, and 10 to 17% based on symptoms (6).

Denervation of the hip is being investigated to address hip OA that is refractory to medical management in nonsurgical candidates. Hip denervation via chemical/surgical techniques has fallen out of favor due to its increased risk of neuritis and/or deafferentation pain, when compared with percutaneous radiofrequency ablation (RFA), which has a lower incidence of these complications (2). Hip RF was first studied in cancer population in 2 modalities, either for relief of pain associated with primary lesions or metastasis to the hip or in direct ablation of tumors in the acetabular/femoral head region. This technique has since been extrapolated for application in a different cohort for treatment of inoperable hip arthrosis.

RF is already commonly used along the spine for facetogenic axial neck and back pain with great success. Though RF systems have continued to evolve, increasing the treatment's popularity for use in patients with all types of chronic articular pain, the body of evidence-based literature for its use in nonmalignant hip pain is overall lacking. There are case reports of varying degrees of success with RF technique on the obturator and femoral nerves as they relate to coxalgia. However, the few published studies that exist have differing techniques and duration of reported relief (7,8).

There are different subtypes of RF, with the classical and first use being thermal. Pulsed RF and cold RF have since been employed in this population. Due to overall paucity of literature, our review will focus on studies using thermal and pulsed RF. Cold RF will be excluded due to very few case studies found while introducing considerable differences in equipment and methods.

For the reasons described above, a systematic review of the existing literature was performed to examine available evidence for thermal and pulsed RF treatment for chronic hip pain. To prevent ambiguity, this review will focus only conventional and pulsed RF treatment on a non-cancer patient population with either refractory or inoperable chronic coxalgia.

## **METHODS**

### **Eligibility Criteria**

This systematic review is conducted according to the PRISMA-guidelines (<http://www.prisma-statement.org/>).

A PICOS-approach was applied to formulate the research question: patient (P), intervention (I), comparison (C), outcome (O), and study design (S). This systematic review attempted to select those articles which described “estimated effectiveness (O) of pulsed or thermal RF (I) treatment for chronic nonmalignant hip-related pain in adults (P). Studies were included if they used either conventional thermal or pulsed RF therapy in non-cancer patients and (C) compared pain score pre- and post-procedure in some capacity. Due to lack of patients, case studies and clinical trials were included (S).

### **Search Strategy**

A systematic review of the existing (English and nonEnglish) literature was performed on 1/20/2017. The following electronic databases were screened: PubMed (1960-2017), the Cochrane Controlled Trials Register (1960-2017), and EMBASE (1966-2017). Search terms included RF, hip, and human (“radiofrequency”[All Fields]AND (“hip”[MeSH Terms] AND “humans”[MeSH Terms])).

### **Study Selection**

After removing duplicates, the remaining articles were filtered by the selection criteria by reviewing the title and abstract. Then, full texts of the remaining articles were screened against the same criteria to confirm eligibility. The inclusion criteria consisted of the following: (1) living human adults ( $\geq 18$  years old); (2) chronic hip pain defined as  $\geq 3$  months; (3) intervention consists of thermal or pulsed RF treatment of articular branches of femoral or obturator nerves; (4) case reports, case series, clinical trials; (5) full texts. Exclusion criteria were (1) malignant hip pain; (2) cold RF; (3) surgery involved during anytime between intervention and follow-up; (4) intraarticular neurolysis; (5) nerve blockade alone; (6) RF of nonnerve target. Outcome measures included pain scores, analgesic requirements, and functional improvement following the procedure. Eligibility assessment was performed independently in an unblinded standardized manner by 2 reviewers. Disagreements between reviewers were resolved by consensus.

### **Risk of Bias in Individual Studies**

There is tremendous risk of bias in the included studies due to lack of blinding and small sample sizes. However, these reports were included due to the small number of available studies.

### Risk of Bias Across Studies

Due to the positive reporting biases and small sample sizes in individual studies and case reports, there was also a large risk of bias across all studies included.

### Data Extraction

For each trial, the following information was extracted: (1) characteristics of trial patients (including age and severity of disease), and the trial's inclusion and exclusion criteria; (2) type of intervention (including type, dose, duration and frequency of RF application) (3) type of outcome measure (including the level of pain reduction using a validated scale), and duration of relief.

### Synthesis of Results

Because of the variability in the reports and the lack of large, randomized controlled trials, no meta-analysis was performed. However, information regarding the individual trials is summarized in Table 1 (1,9-17).

## RESULTS

The search of PubMed, Cochrane Controlled Trials Register, and EMBASE databases provided a total of 289 citations. After adjusting for duplicates 228 remained. Of these, 213 studies were discarded because after reviewing the abstracts it appeared that these papers clearly did not meet the criteria. Six additional studies were discarded because the intervention was not thermal or pulsed RF (cold RF in 3 studies, intraarticular RF in 1 study, and no intervention in 2 studies). The full text of the remaining 10 citations was examined in more detail and included in the systematic review. No unpublished relevant studies were obtained. See flow diagram (Fig. 1).

A total of 10 studies including only 2 clinical trials were found to be eligible after screening title, abstract, and full text for inclusion and exclusion criteria, encompassing a total of 58 patients. Most published evidence comes from single case reports and small case series. There were concerns about risk of bias in most studies, especially about blinding of patients and personnel (performance bias) and blinding of outcome assessment (detection bias).

Overall, studies were low quality based on GRADE Working Group grades of evidence. The first large case series published by Kawaguchi et al (1), who

performed thermal RF in 14 patients found significant pain relief (at least 50%) in 12 patients, lasting 3 to 9 months. Total duration of follow-up was one year. Both clinical trials noted high mean baseline VAS scores that improved post procedure, when compared with status quo conservative treatment for inoperable chronic hip pain. Rivera et al (12) undertook a randomized, nonblinded, noncontrolled study of thermal RF in 17 patients. Eight patients reported a decrease in pain of at least 50% at 6 months, with widely varying VAS at follow-up. More recently, results for another nonrandomized, nonblinded controlled trial including 15 patients demonstrated significant clinical benefit with pulsed RF versus placebo, that lasted for the duration of follow-up (12 weeks).

The collection of case studies similarly found generally improved pain scores after either thermal or pulsed RF treatment. However, the overall certainty in the evidence was judged as low because of the risk of bias, inconsistency of results among studies, limited patient numbers, and heterogeneity of the whole body of evidence.

Most case reports describe the application of thermal RF in this population. Fukui and Nosaka first reported results in a single case with excellent pain relief lasting over 2 years (9). Subsequently, Malik et al (10) performed RF in 3 patients with inoperable hip OA and found significant reduction in pain and improvement in function in all subjects, maintained at 12 weeks of follow-up. Chaiban et al (13) first used ultrasound guidance for RF treatment of hip pain in a single patient. RF was performed bilaterally at 1 month interval, resulting in 80% reduction in pain at 3 months. Another case series of 3 patients documented 68% improvement at 4 weeks. Wu and Groner reported results with pulsed RF in 2 patients with chronic hip pain and demonstrated pain relief for 3.5 months (11).

The degree of relief in various studies ranged widely as did duration of appreciable analgesia which was not well defined in many studies. When follow-up was specified, the majority of studies reported at least 1 month of success as defined loosely by appreciable analgesia and satisfaction from the patients. Though it was not included in every study, some studies documented additional measures of success (in addition to VAS scores), which included measuring functional improvement and tracking oral analgesic

62 Table 1. Studies involving conventional and pulsed thermal RFA of periarticular.

Year-Author	Study Design	Sample Size	Pt Selection Characteristics	Intervention/Method	pre-procedure VAS	post-procedure VAS	Duration of Follow-up	Duration of relief	Complications	Conclusions
2001-Fukui (9)	Case report	1	59 yo patient with chronic hip pain from destructive chondropathy due to repeated radiation. No metastasis or primary tumor in hip. Contraindications to surgery due to lymphedema and increased infection risk.	3 mL 1% Lidocaine diagnostic block performed first. Under fluoroscopy and sensory/motor stimulation for localization, thermal RFA performed with 22-gauge needle, 100 mm electrode with 4 mm exposed tip. 90°C for 180 sec at each branch.	9.5 [range 9-10]	1.5 [range 1-2]	2 years	> 2 years	no complications noted	thermal RFA can be option for analgesia of chronic hip pain due to OA for patient with contraindications to surgery
2001-Kawaguchi (1)	Case-series	14	Patients > 18 yo. Contraindications for THA, causes: Osteoarthritis (n = 8), persistent postoperative pain (n = 4), metastasis* (n = 2)	Thermal RFA of either obturator only (n = 9) or both obturator and femoral branches (n = 5) under fluoroscopy; Localization with sensory stimulation; 2 mL 1-2% Mepivacaine injected before each site; 75-80°C for 90 seconds	6.8 [SD 0.9]	2.7 [SD 1.3]	1 year	*3-9 months	no complications noted	*2 of 14 patients had oncologic origin of hip pain which skews overall data. Excluding these patients would conclude 3-9 months of relief. Patients not controlled for # of sites (obturator vs obturator + femoral). No significance calculated. "Relief" not defined for determining duration. Percutaneous radiofrequency lesioning of these nerves can be an alternative therapeutic tool in patients with hip joint pain, especially in patients for whom operation is not applicable.
2003-Malik (10)	Case-series	*3	Patients > 18 yo. Patients with chronic anterior/medial hip pain without surgical options due to comorbidities. Excluded lower back pain, posterior/buttock pain as confounding pain generators. Etiologies: AVN, s/p trauma, OA. *Did not include 1 patient who had metastasis to hip.	All received diagnostic block with 1mL of 0.25% Bupivacaine prior to RFA under fluoroscopy. 2 patients with thermal RFA with 75-80°C for 90 seconds. One patient with pulsed RF without otherwise defined parameters.	*8.2 [range 7 - 9.5]	4 week f/u: 3 [range 2-4]; 8 week f/u: 3 [range 2-4]; 12 week f/u: 4	12 weeks	> 12 weeks	1 incidence of persistent lateral surface hip numbness (unknown duration)	*Removed 1 of the 4 case studies due to cancer involvement. Other VAS results were averaged on own. Need more data collected but RFA is a reasonable approach to chronic hip pain when surgery is not an option. Effectiveness rate linked to correct diagnosis of etiology of hip pain.
2007-Wu (11)	Case-series	2	no selection criteria specified. Etiology: OA s/p TKA with persistent pain, AVN nonsurgical candidate	All received diagnostic block with 0.5 - 1 mL of 1% Lidocaine prior to pulsed RFA under fluoroscopy. 2x 20 ms/sec generator output 45 V for 120 sec at 42°C x 2 cycles	9 [range 8-10]	0 immediately post-procedure; average 3.5 at 3-4 months	3 months for one patient, 4 months for other	> 3 months	no complications noted	Documentation of VAS not consistent between two patients. Pulsed RF may be more attractive option vs thermal RF for chronic hip pain.
2012-Rivera (12)	Randomized, non-blinded, controlled trial.	17	Patients > 18 yo. Contraindications for THA, radiographic Tönnis grades I and II for Osteoarthritis; persistent postoperative pain; chronic hip pain defined by pain in groin, thigh, and trochanteric pain. Successful diagnostic block with 3 mL of 1% Ropivacaine.	Thermal RFA of both obturator and femoral branches under fluoroscopy; 22-gauge electrode 5 mm exposed tip; Localization with sensory stimulation; 1 mL Lidocaine before each site; 90°C for 90 seconds	9.52 [range 7-10; SD 0.79; P < 0.05]	6 months: 6.35 [range 3-10; SD 2.17; P < 0.05]	6 months	> 6 months	3 cases of transient hematoma from vessel puncture	Variable intervention timing (5-16 days) post-diagnostic block. Only included Tönnis Gr1 & 2 (out of 3). Short followup with unknown true duration of relief; Large range in 6-month VAS. Changed approach halfway through study from perpendicular to more lateral approach 2/2 hematomas. Used sensory/motor testing in WOMAC and Harris Hip Scores pre and post procedure to ensure no motor complications. Percutaneous radiofrequency lesioning of the sensory branches of the nerves innervating the hip joint can be an option for patients with intractable hip joint pain and an alternative treatment of hip arthritis with contraindications for THA

Table 1 cont. Studies involving conventional and pulsed thermal RFA of periarticular.

Year- Author	Study Design	Sample Size	PI Selection Characteristics	Intervention/Method	pre-procedure VAS	post-procedure VAS	Duration of Follow-up	Duration of relief	Complications	Conclusions
2014-Chaiban (13)	Case report	1	80 yo patient, persistent post-surgical pain s/p ORIF for hip fracture. Poor surgical candidate due to medical comorbidities	Thermal RFA of both obturator and femoral branches under fluoroscopy and ultrasound. 22-gauge electrode w/5 mm exposed tip. 2 mL 0.25% Bupivacaine given prior to lesioning. 80°C for 60 seconds	not reported	> 80% improvement	3 months	3 month+?	no complications noted	conventional RFA used in a lateral approach combined with ultrasound can better avoid vascular structures while achieving pain relief
2014-Cortinas-Saenz (15)	Case-series	3	Patients > 18 yo. Chronic hip pain due to avascular necrosis of femoral head and either delayed surgery (n = 2) or contraindication to surgery due to medical comorbidities (n = 1).	All received diagnostic block with unspecified amount of 0.25% Levobupivacaine prior to RFA under fluoroscopy. thermal RFA with 75-90°C for 90 seconds. 22-gauge needle 10 cm with 10 mm active tip	not reported	average 68.3% improvement at 4 weeks	6 months	> 6 months	1 incidence of persistent lateral surface hip numbness (unknown duration)	Blocking sensory branches of obturator and femoral nerves can be effective solution to patients with chronic hip pain with delay in or contraindication to surgery. Diagnostic block limited in duration of relief but can be helpful in predicting effectiveness of subsequent RFA.
2014-Gupta (16)	Case report + literature review	1	55 yo patient with significant chronic hip pain from OA. On waitlist for THA.	History of intraarticular injections with temporary response in past, therefore skipped diagnostic block specifically for RFA. Thermal RFA done with 10cm needle with 10 mm active tip. 80°C for 120 sec x 2 treatments for obturator and femoral branch each.	not reported	Two treatments performed on same target during wait-list time. 1st = 90% relief ;2nd = 20-50% relief	1st = 6 months; 2nd = inconclusive due to receiving surgery at 4 months	6 months	no complications noted	Hip joint radiofrequency denervation is a viable adjunct for treatment of chronic hip pain. There are still many unknowns regarding technical approaches and parameters which can be assisted with further cadaveric studies. Inferolateral approach may have some benefitsFuture clinical studies with more patients need to be done and should consider pain, functional, and economic outcomes in their design.
2015-Chye (14)	Non-randomized, non-blinded, controlled trial	15	Patients > 18 yo. Contraindications for THA, radiographic Tönnis grades I and II for osteoarthritis, chronic hip pain > 3 months. Excluded: osteonecrosis, post-surgical pain, patients on anticoagulation. Patients volunteered for PRF arm of study vs. control.	pulsed RF of both femoral and obturator nerve branches under fluoroscopy; localized with sensory stimulation; 22-gauge 10 mm needle; 2% lidocaine before PRF; 2, 180 second cycles of PRF (RF current 20 ms at 45 V), temperature not exceeding 42°C	6.7 [SD 0.6, P 0.981]	1 week 2.2 +/- 1.5; 4 week 2.4 +/- 1.4 ; 12 week 3.0 +/- 1.8	12 weeks	> 12 weeks	1 subcutaneous hematoma	PRF of the articular branches of the femoral and obturator nerves offers a treatment option with good outcomes for patients suffering from chronic hip pain. When compared with conservative treatment, it offers greater pain relief and can augment physical functioning.
2016-Austria (17)	Case report	1	53 yo patient, nonsurgical candidate with bilateral hip OA	Conventional radiofrequency (single needle) technique provided only four weeks of pain reduction. Second procedure used a bipolar radiofrequency approach was to provide larger lesion size in order to account for variability in nerve location and size	not reported - Lower Extremity Functional Scale 18/80	Lower Extremity Functional Scale 49/80	6 months	6 months	no complications noted	Bipolar radiofrequency ablation using a perpendicular (AP) approach improves functional status for nonsurgical candidates with intraarticular hip pain

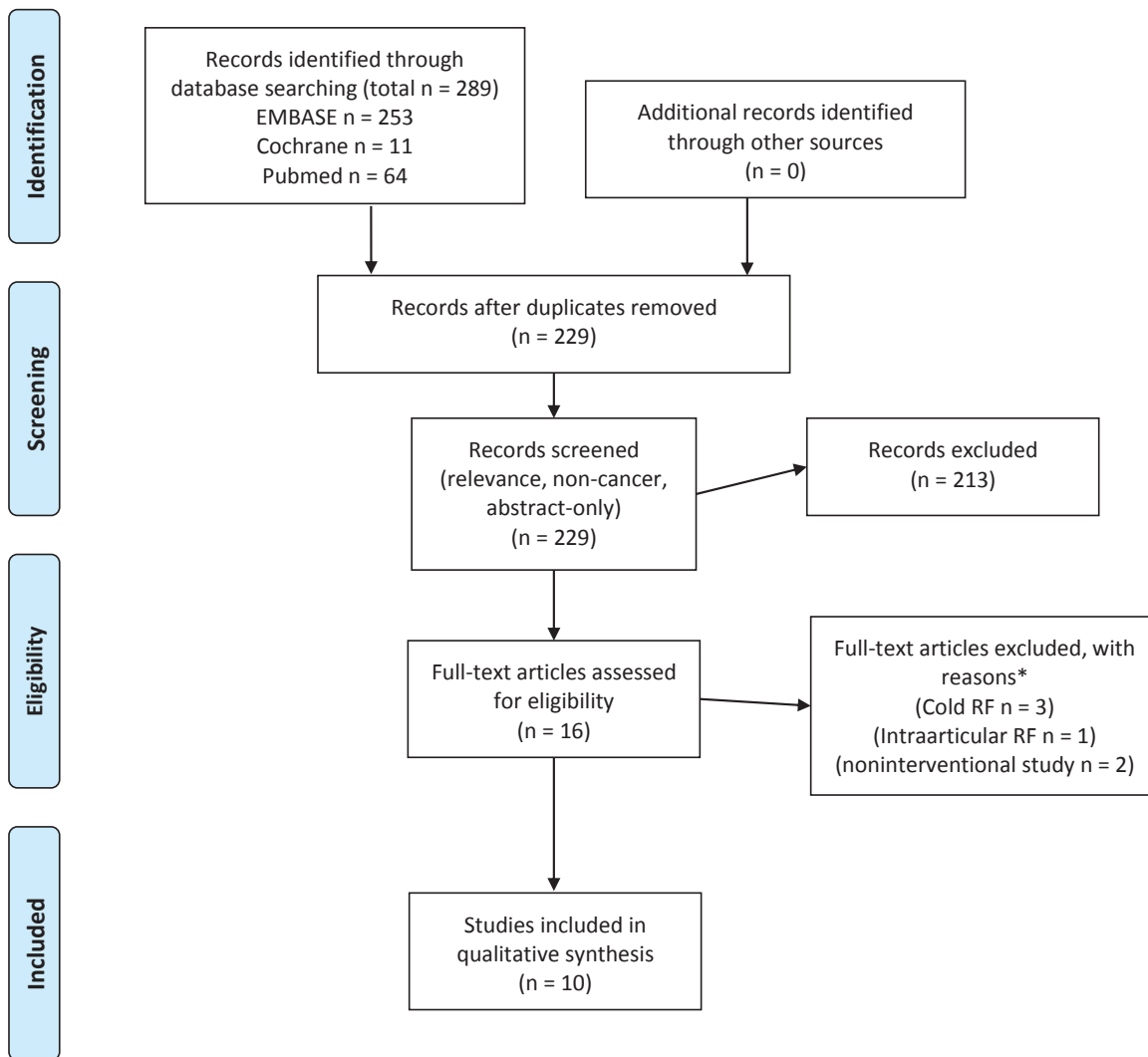


Fig. 1. PRISMA RFA flow diagram.

requirements. Due to the absence of these measures in a significant number of the included studies, these attributes were omitted in our overall analysis (Table 1). Overall complication rate of pooled cohort of all cases reviewed was 9.5% (6/57) but did not result in any self-reported injury. Adverse effects were typically mild and transient, mainly limited to hematoma formation in the study by Rivera et al (10) and this appears to be minimized by the lateral needle approach. There was one report of persistent numbness of the hip related with thermal coagulation.

## METHODS

### Characteristics of Included Studies

All 10 studies finally selected for the review were published in English. Interventions consisted of either 2 cycles of 120-180 seconds of pulsed RF at 42°C (240-360 seconds total) or thermal RF 75-90°C for 60-180 seconds. The duration of follow-up was 12 weeks to 1 year. The most commonly used needle size was 22-gauge. Most reported using local anesthetic prior to the RF procedure.

## Patients

The included studies involved 38 patients. The main inclusion criteria entailed adults (18 years or older), nonmalignant chronic hip pain that was nonsurgical in nature.

## Intervention

Trials were not blinded, and only one had a control group, in which patients volunteered to either undergo the intervention or to receive standard therapy. Pulsed or thermal RF was used on the periarticular branches of the obturator and/or femoral nerve in all studies. Approaches to the femoral and obturator nerve varied, though most favored an approach lateral to medial with a fluoroscopic view 70 degree obliqued toward the ipsilateral side from the sagittal/perpendicular plane and a 20 degree craniocaudal angulation from the transverse plane. Though all studies were performed with intermittent fluoroscopic guidance, case studies by Gupta et al (4) and Chaiban et al (13) included the additional use of live ultrasound guidance for additional assurance that vascular structures were avoided in the lateral approach.

## OUTCOMES

### Primary

In all studies the primary outcome assessed was VAS score after the procedure. All studies evaluated adverse effects, including those of any kind and serious events.

### Secondary and Additional Outcomes

These included post procedure analgesic requirements and functional improvements. Complications included one case of lateral thigh numbness when thermal RF was used, and 4 cases of transient hematoma in the area of needle placement related to vessel puncture.

No study included mortality and costs as outcome.

The timing of outcome measures was variable (Table 1) (1,9-17).

## DISCUSSION

Currently available evidence is not sufficiently robust to determine the comparative effectiveness of thermal or pulsed RF against medical treatment alone for nonmalignant, nonsurgical hip pain because of the im-

precision of the estimates of effect on treatment outcomes. Only 2 studies consisted of clinical trials, and neither included randomization or blinding. Though all showed positive results from the intervention, the evidence is weak. Due to the paucity of literature and expert consensus it is not surprising to find that there were variations in the approach to accomplishing RF of the femoral and most importantly, the obturator articular branches. The obturator nerve branches are located almost directly underneath vasculature, with the target endpoint at the inferior aspect of the junction of the pubis/ischium, just superior to the 'teardrop' of the obturator foramen in anteroposterior (AP) view; the femoral target is more superolateral from where the vessels run.

In 2001 Kawaguchi et al (1) published one of the first well-described approaches that reflected the common approach taken when the procedure was done at that time. This traditional approach was done in an AP view and trajectory that would be perpendicular to the transverse axis. In 2008 Locher et al (18) performed an anatomical study involving 10 cadaveric dissections and MRI analysis of 20 patients. It confirmed that though there was variability in the location of the articular branches of both the femoral and obturator nerves, they were overall concentrated anatomically in the target locations as described in previous methods. Notably, the study demonstrated that an AP approach would pass through/very near vascular structures in the inguinal region (femoral artery/vein) in a majority of the patients sampled for anatomic variability. They proposed an approach lateral to medial with a fluoroscopic view 70 degree obliqued toward the ipsilateral side from the sagittal/perpendicular plane and a 20 degree craniocaudal angulation from the transverse plane. Authors in subsequent studies generally favored this approach and reference Locher's method as described in his 2008 study (18). In 2012, Rivera et al (12) even changed the approach from an AP perpendicular insertion to Locher's lateral approach for the latter half of the patients in that study after noticing an increased incidence of hematoma at the obturator branch site. Though all studies were performed with intermittent fluoroscopic guidance, there were several case studies that included the additional use of live ultrasound guidance for additional assurance that vascular structures were avoided in the lateral approach (4,13).

While the vast majority of reports employed thermal RF, 2 publications undertook pulsed RF (11,14). Although pulsed RF is associated with less tissue destruction and good analgesia, the required perpendicular needle placement and close proximity to the neurovascular structures warrants approach with caution.

## Limitations

### Outcome Level

Our review comprehensively summarizes current evidence about using thermal and pulsed RF treatment for nonmalignant hip pain. Our extensive search of several literature databases enhanced by reviewing the citations in identified studies and reviews makes it unlikely that any relevant study was missed. However, the review reported here was unable to provide a meta-analysis in order to estimate treatment effects due to the low quality of available studies. The main limitation of this synthesis, as with any overview, is that the patient population, intervention strategy and the outcome definitions are not the same across studies.

### Study and Review Level

Our study has several major limitations. The quality of the studies varied. Only 2 studies were clinical trials as opposed to case studies, and these trials were unblinded and not randomized. All trials used small sample sizes. There was inconsistent and sometimes flawed methodology in patient selection, with a heterogeneous etiology of pain, variable needle placement technique, as well as variable temperature and duration of RF, lack of (standardized) measurement of functional outcomes, and undefined or short follow-up period for majority of studies < 1 year. However, all studies showed a positive effect of pulsed or thermal RF on the femoral or obturator nerves for at least 1 month post procedure.

Publication bias might account for some of the effect we observed. Smaller trials are, in general, analyzed with less methodological rigor than larger studies, and many of the studies collected in this review were case series or reports.

## CONCLUSIONS

### Implications for Practice

In the limited existing body of evidence, traditional

and pulsed RF therapy has resulted in varying degrees of successful short term (> 1 month) improvement in VAS scores for adults with chronic inoperable coxalgia. Longevity and clinically significant impact of pain relief is not well-defined and often not quantified with the potential duration of pain improvement outlasting a short follow-up period. Multiple studies that were reviewed showed a predictive association between effectiveness of diagnostic blocks with local anesthetic and efficacy of subsequent RF for coxalgia if diagnostic block was effective. Intervention varied considerably in some respects (pulsed vs. thermal and approach) while others (duration, settings, targets) only slightly, but overall were not controlled among the heterogeneous collective sample reviewed in this article. These inconsistencies are duly noted in this review and, along with a small pooled sample, introduce a high degree of variability. Complications were broadly defined as unintended effects from the intervention. Complication rate in the pooled analysis of patients from studies reviewed is considerable at 9.5%, however effects are generally minor and include: hematoma from vascular puncture during procedure and persistent (though of unquantified duration) anesthesia of certain dermatomes around hip.

For nonsurgical hip pain, or chronic hip pain after hip replacement, there are limited options available outside of steroid injections and medications. Unfortunately, for patients who fail steroid injections, pharmacologic options often fall back on opioid therapy. Given the current opioid epidemic, there is a great need for nonpharmacologic options to manage chronic pain. In cancer patients, opioids can often be effectively utilized because there is a limited time during which opioid therapy is needed for terminal illnesses. However, in non-cancer patients who have chronic pain, opioids often need to be escalated over time to compensate for tolerance, and can lead to increased side effects with decreased analgesia. As such, RF for the treatment of hip pain in these patients appears to be a viable option for pain management with a low incidence of adverse events.

### Implications for Research

A logical next step would be the development of a randomized control trial that is double-blinded to obtain a higher level of evidence and reduce the overall risk of bias. Comparative studies of cooled vs. pulsed vs. conventional thermal RF should also be performed



in order to better delineate which methods produce maximal pain relief with minimal complications at this site. Increased use of nonpharmacologic methods for the management of chronic pain can improve patient quality of life and decrease reliance on and side effects from medications such as opioids.

### **Acknowledgment**

Two of the authors (Dr. Kalangara and Dr. Woodbury) were employees of the U.S. Federal Government when this work was conducted and prepared for publication. Hence, it is not protected by the Copyright Act, and copyright ownership cannot be transferred.

**Author Contributions:** Drs. Kao, Kalangara, and Woodbury had full access to all the data in the study and takes responsibility for the integrity of the data and the accuracy of the data analysis. Drs. Kao and Woodbury designed the study protocol. Drs. Kao and Kalangara managed the literature searches and summaries of previous related work and wrote the first draft of the manuscript. Dr. Woodbury provided revision for intellectual content and final approval of the manuscript. All authors provided input into the revision of the article for resubmission following the Review-

er's response. **Conflict of Interest:** All authors have no conflicts of interest to report. None of the authors of the manuscript received any remuneration. Further, the authors have not received any reimbursement or honorarium in any other manner. The authors are not affiliated in any manner with industry. However, all the authors are members of the Atlanta Veterans Affairs Medical Center and practicing interventional pain physicians except for Gary Kao, who is an interventional pain fellow. Dr. Woodbury has received Funding/Support that began August 1, 2017 from a federally funded Career Development Award (CDA-1) through the Veteran's Affairs Rehabilitation Research and Development Service (RR&D). We also would like to thank the editorial board of Pain Physician for review and criticism in improving the manuscript.

### **Funding**

The senior investigator on this manuscript has received federal funding/support through the Veteran's Affairs Rehabilitation Research and Development Service (RR&D). The publication is not subject to copyright.

## REFERENCES

1. Kawaguchi M, Hashizume K, Iwata T, Furuya H. Percutaneous radiofrequency lesioning of sensory branches of the obturator and femoral nerves for the treatment of hip joint pain. *Reg Anesth Pain Med* 2001; 26:576-581.
2. Kim PS, Ferrante FM. Cryoanalgesia: A novel treatment for hip adductor spasticity and obturator neuralgia. *Anesthesiology* 1998; 89:534-556.
3. Murphy L, Helmick CG. The impact of osteoarthritis in the United States: A population-health perspective. *Am J Nurs* 2012; 112:S13-S99.
4. Gupta S, Hawker GA, Laporte A, Croxford R, Coyte PC. The economic burden of disabling hip and knee osteoarthritis (OA) from the perspective of individuals living with this condition. *Rheumatology (Oxford)* 2005; 44:1531-1537.
5. Felson DT, Lawrence RC, Dieppe PA, Hirsch R, Helmick CG, Jordan JM, Kington RS, Lane NE, Nevitt MC, Zhang Y, Sowers M, McAlindon T, Spector TD, Poole AR, Yanovski SZ, Ateshian G, Sharma L, Buckwalter JA, Brandt KD, Fries JF. Osteoarthritis: New insights. Part 1: The disease and its risk factors. *Ann Intern Med* 2000; 133:635-646.
6. Jordan JM, Helmick CG, Renner JB, Luta G, Dragomir AD, Woodard J, Fang F, Schwartz TA, Nelson AE, Abbate LM, Callahan LF, Kalsbeek WD, Hochberg MC. Prevalence of hip symptoms and radiographic and symptomatic hip osteoarthritis in African Americans and Caucasians: The Johnston County Osteoarthritis Project. *J Rheumatol* 2009; 36:809-815.
7. Heywang-Kobrunner SH, Amaya B, Okoniewski M, Pickuth D, Spielmann RP. CT-guided obturator nerve block for diagnosis and treatment of painful conditions of the hip. *Eur Radiol* 2001; 11:1047-1053.
8. Edmonds-Seal J, Turner A, Khodadadeh S, Bader DL, Fuller DJ. Regional hip blockade in osteoarthrosis. Effects on pain perception. *Anaesthesia* 1982; 37:147-151.
9. Fukui S, Nosaka S. Successful relief of hip joint pain by percutaneous radiofrequency nerve thermocoagulation in a patient with contraindications for hip arthroplasty. *J Anesth* 2001; 15:173-175.
10. Malik A, Simopolous T, Elkersh M, Aner M, Bajwa ZH. Percutaneous radiofrequency lesioning of sensory branches of the obturator and femoral nerves for the treatment of non-operable hip pain. *Pain Physician* 2003; 6:499-502.
11. Wu H, Groner J. Pulsed radiofrequency treatment of articular branches of the obturator and femoral nerves for management of hip joint pain. *Pain Pract* 2007; 7:341-344.
12. Rivera F, Mariconda C, Annaratone G. Percutaneous radiofrequency denervation in patients with contraindications for total hip arthroplasty. *Orthopedics* 2012; 35:e302-e305.
13. Chaiban G, Paradis T, Atallah J. Use of ultrasound and fluoroscopy guidance in percutaneous radiofrequency lesioning of the sensory branches of the femoral and obturator nerves. *Pain Pract* 2014; 14:343-345.
14. Chye CL, Liang CL, Lu K, Chen YW, Liliang PC. Pulsed radiofrequency treatment of articular branches of femoral and obturator nerves for chronic hip pain. *Clin Interv Aging* 2015; 10:569-574.
15. Cortinas-Saenz M, Salmeron-Velez G, Holgado-Macho IA. [Joint and sensory branch block of the obturator and femoral nerves in a case of femoral head osteonecrosis and arthritis]. *Rev Esp Cir Ortop Traumatol* 2014; 58:319-324.
16. Gupta G, Radhakrishna M, Etheridge P, Besemann M, Finlayson RJ. Radiofrequency denervation of the hip joint for pain management: Case report and literature review. *US Army Med Dep J* 2014; 41-51.
17. Austria RP, Macedo F. Poster 452 bipolar radiofrequency ablation for the treatment of hip joint pain using a perpendicular approach: A case report. *PM R* 2016; 8:S308.
18. Locher S, Burmeister H, Böhlen T, Eichenberger U, Stoupis C, Moriggl B, Siebenrock K, Curatolo M. Radiological anatomy of the obturator nerve and its articular branches: Basis to develop a method of radiofrequency denervation for hip joint pain. *Pain Med* 2008; 3:291-298.